

CHAPTER 2

GRAFTS AND FLAPS

Skin protects the body from outside invaders and prevents loss of fluids, electrolytes, proteins, etc. Skin may be replaced by spontaneous epithelialization and contraction or by a graft or flap.

I. SKIN GRAFT

A skin graft is skin separated completely from its bed (donor site) and transplanted to another area (recipient site) from which it must receive a new blood supply.

A. Classification

1. By species

- a. Autograft — graft from one place to another on the same individual
- b. Allograft (homograft) — graft from one individual to another of the same species
- c. Xenograft (heterograft) — graft from one individual to another of a different species

2. By thickness (Fig. 2-1)

a. Split thickness

- i. Includes epidermis and part of dermis
- ii. Some dermal skin appendages (sweat glands, hair follicles and sebaceous glands) remain, from which donor site heals by epithelialization
- iii. Thickness varies from thin to thick
 - (a) A higher percentage of "take" (survival) is more likely with a thinner graft
 - (b) Recipient site wound contraction is less with a thicker graft

iv. Uses

- (a) Large areas of skin loss
- (b) Granulating tissue beds
- (c) May be meshed to allow increased area of coverage

v. Harvesting methods (Fig. 2-2)

- (a) Free hand (razor blade or knife)
- (b) Dermatomes (drum or power driven "hair clipper" type machines)

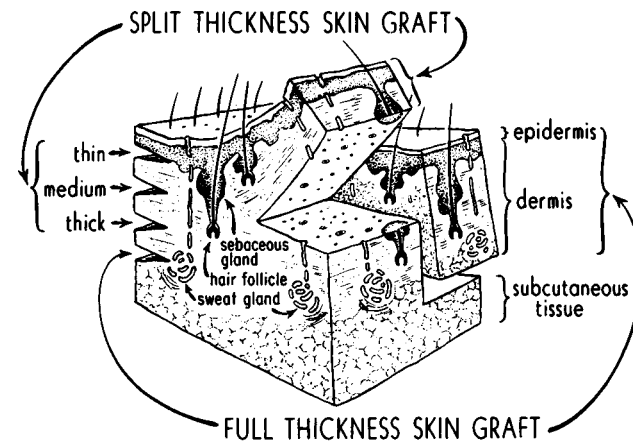


Fig. 2-1

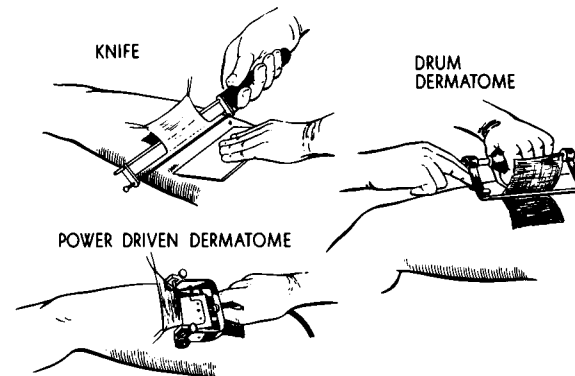


Fig. 2-2

vi. Donor site

- (a) Heals by epithelialization from wound edges and from skin appendages
- (b) A moist environment (e.g. bacitracin, impregnated gauze) hastens epithelialization

- (c) Requires care to prevent infection which can convert it to full thickness skin loss
 - b. Full Thickness
 - i. Includes epidermis and all dermis
 - ii. Provides better coverage but is less likely to “take” than a split thickness skin graft because of greater thickness and slower vascularization
 - iii. Donor site is full thickness skin loss and must be closed primarily or with a split thickness skin graft
 - iv. Uses
 - (a) Usually on the face for better color match
 - (b) On the finger to avoid contractures
 - (c) Anywhere that thick skin or less contraction of the recipient site is desired
 - v. Limited by size of defect to be closed
 - c. Skin Substitutes
 - i. Temporary skin coverage
 - ii. Homograft — cadaver skin
 - iii. Xenograft — pig skin
 - iv. Biobrane® — bilamellar synthetic skin
 - v. Alloderm® — human acellular dermis
 - vi. Integra® — bilamellar synthetic skin
- B. Donor site selection
 - 1. Determined by amount and thickness of tissue needed
 - 2. Best taken from inconspicuous areas (e.g. buttock or high lateral thigh for split thickness, groin for full thickness)
 - a. Be conscious of hair patterns when skin appendages included
 - 3. Color match is important especially when grafting the face
 - a. Best achieved by using the closest appropriate area above the clavicle (e.g. postauricular, upper eyelid, supraclavicular, scalp)

- C. Graft survival
 - 1. Both split and full thickness grafts “take” initially by diffusion of nutrition from the recipient site (plasmatic imbibition)
 - 2. Revascularization generally occurs between day 3-5 by either reconnection of blood vessels in the graft to recipient site vessels inosculation or by ingrowth of vessels from the recipient site into the graft
 - 3. All grafts must be placed on well-vascularized beds with low bacterial counts ($<10^5$) to maximize chance of “take”
 - 4. The graft must be immobilized to minimize shearing of the graft from the bed and/or hematoma formation, which separates the graft from its bed and prevents diffusion of nutrients, ingrowth of new vessels, and subsequently less “take”
 - 5. Skin grafts generally will not “take” on poorly vascularized beds such as bare tendons, cortical bone without periosteum, heavily irradiated areas, infected wounds, etc.
 - 6. Inspection of graft to evacuate seroma/hematoma prior to day 4 may improve graft survival
 - 7. Graft loss most commonly the result of:
 - a. Hematoma/seroma under graft
 - b. Shearing forces between graft and recipient site
 - c. Poorly vascularized recipient site
 - d. Infection/colonization

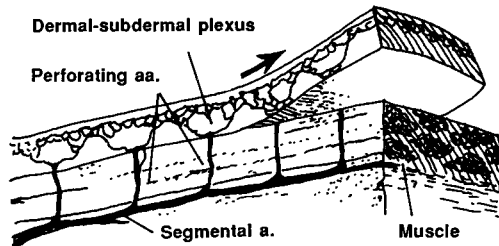
II. FLAPS

A flap is tissue transferred from one site to another with its vascular supply intact. This may consist of skin, subcutaneous tissue, fascia, muscle, bone, or other tissues (e.g. omentum).

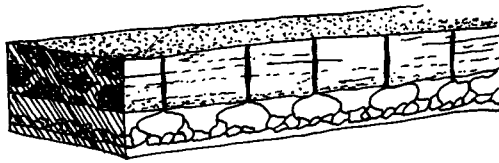
A. Classification

- 1. Random pattern flaps (Fig. 2-3)
 - a. Blood supply is by dermal and subdermal plexus to skin flaps
 - b. Has limited length to width ratio (1.5-2:1)
 - c. Two types:
 - i. Those which rotate (rotation, transposition flaps)
 - ii. Those which advance (single pedicle advancement, V-Y advancement, bipedicle advancement)

RANDOM/RANDOM CUTANEOUS PATTERN SKIN FLAPS




1. Random Cutaneous Flap



2. Myocutaneous Random Flap

Fig. 2-3

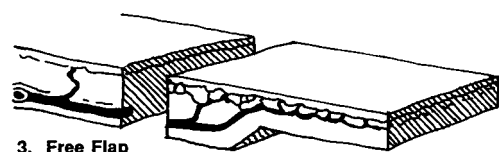
AXIAL/ARTERIAL PATTERN SKIN FLAPS



1. Peninsular Axial Pattern Flap



2. Island Axial Pattern Flap



3. Free Flap

Fig. 2-4

2. Axial pattern flaps (arterial flap) (Fig. 2-4)
 - a. Blood supply by direct artery and accompanying vein
 - b. Greater length possible than with random flap
 - c. Can be free flap, in which the vessels are divided, the flap moved to its new location and the vessels reanastomosed with microsurgical techniques to vessels at the recipient site
 - d. Peninsular — skin and vessel intact in pedicle
 - e. Island — vessels intact, but no skin in pedicle
3. Musculocutaneous flaps (myodermal flaps)
 - a. Compound flaps of skin, subcutaneous tissue, and muscle
 - b. Blood supply of skin and fat comes from blood vessels perforating the muscle (i.e. skin and fat lives off muscle)
 - c. Supplies well-vascularized tissue to defect (e.g. chronic irradiation wound)

B. Uses

1. Replaces tissue loss due to trauma or surgical excision
2. Provides skin coverage through which surgery can be carried out later
3. Provides padding over bony prominences
4. Brings in better blood supply to poorly vascularized bed
5. Improves sensation to an area (nerves to flap skin intact)
6. Brings in specialized tissue for reconstruction such as bone or functioning muscle

III. OTHER GRAFTS

The same basic principles which hold true for skin grafts apply to other grafts.

A. Tendon

1. Used to replace missing or non-functioning tendons
2. Preferred donor sites are palmaris longus and plantaris tendons

- B. Bone
 - 1. Used for repair of rigid defects such as facial bones, skull, and long bones
 - 2. Preferred donor sites are iliac bone, ribs and cranial bone
 - 3. May be taken as vascularized "graft"
- C. Cartilage
 - 1. Used to restore contour of ear and nose
 - 2. Preferred donor sites include costal cartilage, ear, and nasal septum
- D. Fascia
 - 1. Used in repair of dermal defects and in slings for facial nerve palsies
 - 2. Preferred donor sites are fascial lata of thigh and temporalis fascia
- E. Dermis
 - 1. Used for contour restoration such as a depressed scar
 - 2. Some fatty tissue can be included with the dermis to increase its bulk
 - 3. Preferred donor sites are thick skin areas such as the buttock
- F. Muscle
 - 1. Free grafts of skeletal muscle may be useful in selected circumstances but generally must be vascularized and neurotized
- G. Nerve
 - 1. Used to replace nerve gaps, most commonly in the median, ulnar, digital, and facial nerves
 - 2. Preferred donor sites are the sural nerve and forearm and arm cutaneous nerves
- H. Vessel
 - 1. Used to bridge vascular gaps
 - 2. The most common uses are in replantation and in the transfer of free flaps
 - 3. Preferred donor sites include forearm and foot veins for small vessels and the saphenous vein for larger vessels
- I. Fat
 - 1. Used to restore contour defects
 - 2. May be obtained by suction aspiration
 - 3. Variable long term results

- J. Allografts
 - 1. Irradiated cartilage
 - 2. Irradiated acellular dermis
 - 3. Cadaver irradiated bone

CHAPTER 2 — BIBLIOGRAPHY

GRAFTS AND FLAPS

- 1. Mathes, S.J. *Reconstructive Surgery: Principles, Anatomy and Techniques*. New York, Elsevier Science, 1997.
- 2. McCarthy, J.G. (ed). *Plastic Surgery, vol. 1*. New York: Elsevier Science, 1990.
- 3. Russell, R.C. and Zamboni, W.A. *Manual of Free Flaps* New York: Elsevier Science, 2001.
- 4. Serafin, D. *Atlas of Microsurgical Composite Tissue Transplantation*. New York: Elsevier Science, 1996.