

## CHAPTER 6

### UPPER EXTREMITY

The surgical treatment of hand problems is a specialized area of interest in plastic surgery. The hand is a unique organ which transmits sensations from the external environment to us as well as allowing us to modify and interact with the external environment. The hand is made up of many finely balanced structures. It must function with precision, as in writing, as well as with strength, as in hammering. Since the hand is a major tool of interaction with others, it is essential that it look as normal as possible, as well as function well.

#### I. HAND ANATOMY

- A. Surface Anatomy — Knowledge of proper terminology is essential to communicate the location of injuries to others
- B. Nerves
  1. Sensory — median, ulnar, radial (Fig. 6-1)
  2. Motor — intrinsic muscles of hand
    - a. Median nerve — thenar muscles, radial lumbricals
    - b. Ulnar nerve — interossei, ulnar lumbricals, hypothenar muscles

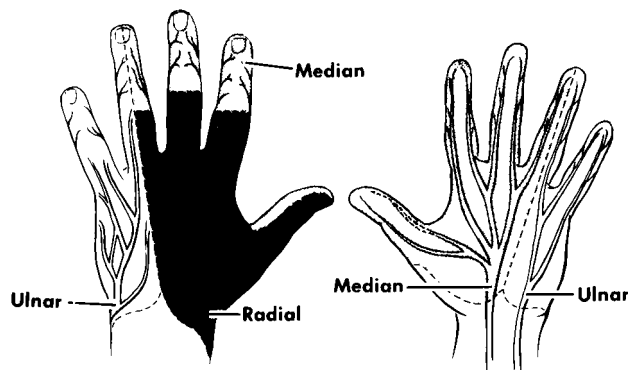


Fig. 6-1

#### C. Muscles and tendons

1. Flexor system (Fig. 6-2)
  - a. Long flexors — Flexor digitorum profundus attaches to distal phalanx and bends the DIP (distal interphalangeal) joint. Flexor digitorum superficialis attaches to middle phalanx and bends PIP (proximal interphalangeal) joint.
  - b. Intrinsic flexors — Lumbricals bend the MCP (metacarpal-phalangeal) joints

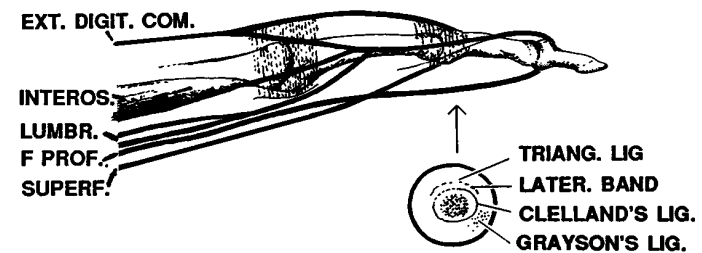


Fig. 6-2

2. Extensor system (Fig. 6-3)
  - a. Long extensors insert on base of middle phalanx
  - b. Intrinsic (interossei and lumbricals) pass volar to the axis of the MCP joint (where they act as flexors) and move dorsal to the axis of the PIP joint to insert on the dorsal distal phalanx. They act as extensors to the PIP and DIP joints

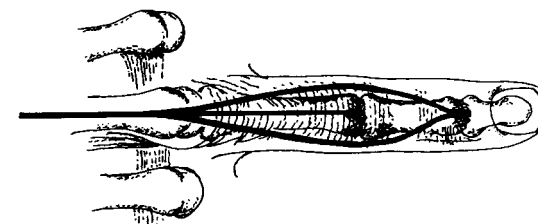


Fig. 6-3

D. Skeleton (Fig. 6-4 — see bibliography page 66)

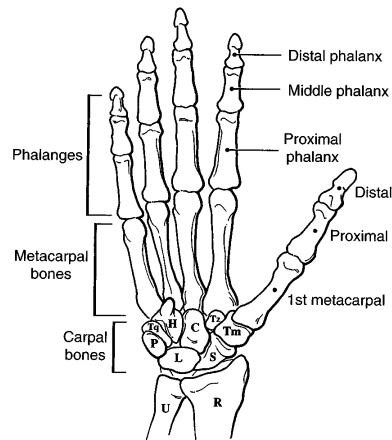


Fig. 6-4\*

E. Wrist — a large number of tendons, nerves and vessels pass through a very small space, and are vulnerable to injury (Fig. 6-5)

**Anatomy at the Wrist**

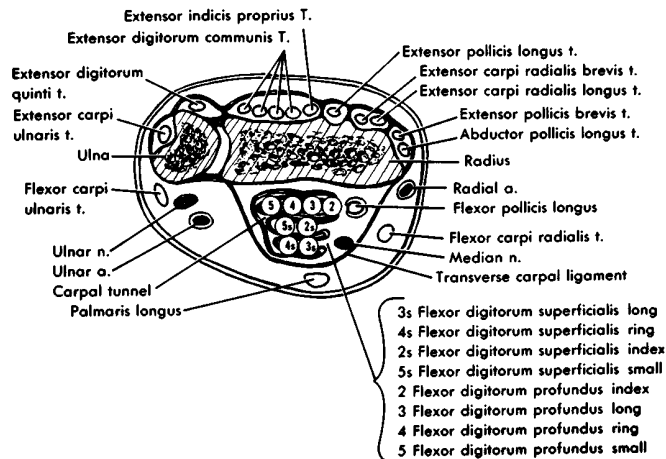


Fig. 6-5

**II. INITIAL EVALUATION OF THE INJURED HAND**

**A. History**

1. Time and place of accident
2. Agent and mechanism of injury
3. First aid given
4. Right or left hand dominance
5. Occupation
6. Age

**B. Examination**

1. Observation
  - a. Position of fingers — normally slightly flexed. An abnormally straight finger might indicate a flexor tendon injury (the unopposed extensors hold the finger straight)
  - b. Sweating patterns (indicate innervation)
  - c. Anatomic structures beneath the injury
2. Sensory — must test prior to administering anesthesia
  - a. Pin to measure sharp/dull sensitivity, paper clip to measure two point discrimination
  - b. Test all sensory territories (median, ulnar, radial)
  - c. Test both sides of each finger
3. Motor
  - a. Profundus — stabilize PIP joint in extension, ask patient to flex fingertip (Fig. 6-6)
  - b. Superficialis — stabilize other fingers in extension. This neutralizes profundus action. Ask patient to flex finger (Fig. 6-7)
  - c. Motor branch of median nerve; test palmar abduction of thumb against resistance
  - d. Motor branch of ulnar nerve; ask patient to fully extend fingers, then spread fingers apart
  - e. Extensor tendons
    - i. Ask patient to extend fingers at MCP joints (tests long extensors)
    - ii. Ask patient to extend PIP, DIP joints with MPs flexed (tests intrinsic extensors)

TESTING PROFUNDUS

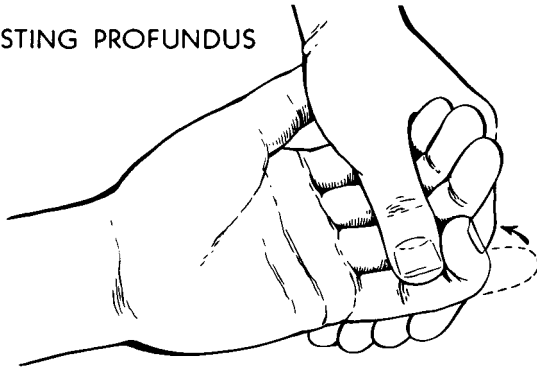


Fig. 6-6

TESTING SUPERFICIALIS

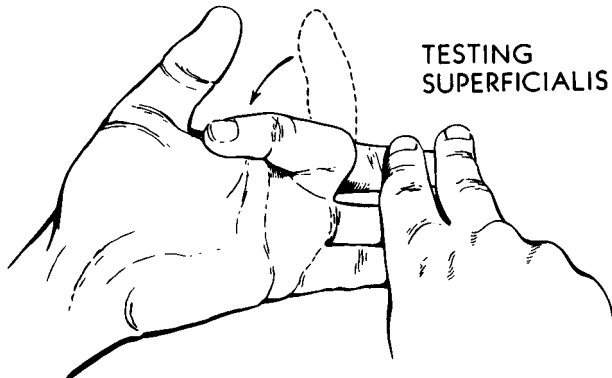


Fig. 6-7

4. Vascular
  - a. Color — nailbed should be pink, blanch with pressure, and show capillary refill within one second
  - b. Temperature — finger or hand should be similar in temperature to uninjured parts
  - c. Turgor — pulp space should be full without wrinkles

C. Early care

1. Use pneumatic tourniquet or BP cuff inflated to 250mmHg to control bleeding for examination and treatment. An awake patient will tolerate a tourniquet for 15-30 min
2. If bleeding is a problem, apply direct pressure and elevate until definitive care available
  - a. Do not clamp vessels
  - b. Tourniquet may be used as last resort, but must be released intermittently
3. Splint in safe position if possible (Fig. 6-8)
  - a. Position where collateral ligaments are at maximum stretch, so motion can be regained with least effort
  - b. Positioning — wrist extended (45°), MCP joints flexed (60°), IP joints straight, thumb abducted and rotated in opposing position
  - c. Proper splinting prevents further injury, prevents vessel obstruction, prevents further tendon retraction
4. All flexor tendon, nerve and vascular injuries, open fractures, and complex injuries are managed in the operating room
5. Tetanus prophylaxis and antibiotic coverage as indicated

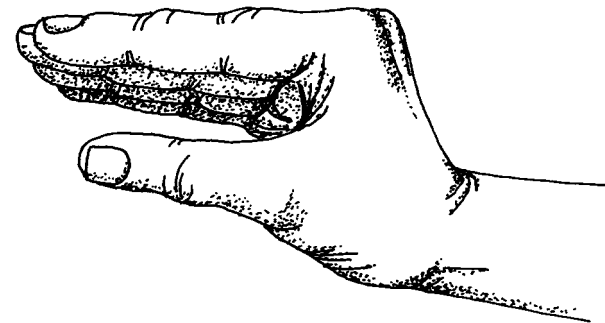


Fig. 6-8

D. Definitive treatment

1. Thorough cleaning of entire hand and forearm, with wound protected
2. Apply sterile drapes
3. Inspect wound — use tourniquet or BP cuff for hemostasis
4. Wound irrigation with normal saline
5. May need to extend wound to inspect all vital structures
6. Assure hemostasis with fine clamps and cautery
7. Nerve injuries should be repaired with magnification
8. Tendons are repaired primarily, except in special instances (e.g. human bite)
  - a. Flexor tendon injuries in Zone II, “no man’s land” (Fig. 6-9) should be repaired by a trained hand surgeon
  - b. If a hand surgeon is not available, clean and suture the skin wound, splint the hand, and refer as soon as possible for delayed primary repair. Repair needs to be done within 10 days
9. Reduce fractures and dislocations, apply internal or external fixation if needed
10. Postoperative dressings
  - a. Splinting should be in safe position when possible, but alternative positioning may be required to protect tendon or nerve repairs
  - b. Dressings should not be tight

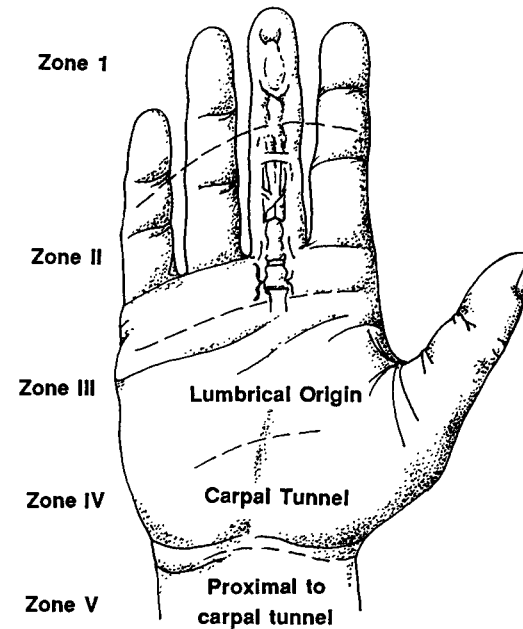
III. SPECIAL INJURIES

A. Fingertip — most common injury

1. Tip amputations
  - a. Basic principles — maintain length, bulk and sensibility
  - b. Treatment options include secondary healing, skin graft, flap
2. Nailbed injury
  - a. Nailbed should be repaired with fine chromic gut suture
  - b. Nail can be cleaned and replaced as a splint, or silastic sheet used as splint to prevent adhesion of the eponychial fold to the nailbed

B. Amputation

1. Indications for replantation — thumb, multiple fingers. Single finger replantations often not indicated. Must discuss with replant team.
2. Care of amputated part
  - a. Remove gross contamination and irrigate with saline
  - b. Wrap part in gauze moistened in saline, place in clean plastic bag or specimen cup, seal
  - c. Lay container on ice, or float on ice cubes in water. Don’t immerse part directly in ice water or pack directly in ice — it may freeze



Flexor zones of hand.

Fig. 6-9

3. Care of patient
  - a. Do not clamp vessels — use direct pressure to control bleeding
  - b. Supportive care
  - c. X-ray stump and amputated part
- C. Burned hand
  1. Initial treatment
    - a. Cleanse wound, debride broken blisters
    - b. Evaluate blood supply — circumferential full thickness burns may require escharotomy
    - c. Apply occlusive dressings to reduce pain
    - d. Immobilize in safe position
    - e. Refer to plastic surgeon if burn is extensive or may require grafting
  2. Hand therapy may be needed to maintain motion

#### IV. INFECTIONS

- A. General principles
  1. Infection can be localized by finding:
    - a. The point of maximum tenderness
    - b. Signs of local heat
    - c. Overlying skin edema
    - d. Pain on movement
  2. A fever usually denotes lymphatic involvement
  3. Pressure from edema and pus in a closed space can produce necrosis of tendons, nerves and joints in a few hours. Extreme cases can lead to amputation and even death
- B. Treatment principles
  1. Surgical drainage, cultures
  2. Immobilization in safe position, elevation
  3. Antibiotics
- C. Specific infections
  1. Paronychia — infection of the lateral nail fold  
Treatment: if early, elevation of skin over nail to drain. If late, with pus under nail, must remove lateral portion of nail
  2. Felon
    - a. Pus in pulp space of fingertip — closed space without ability to expand — very painful
    - b. Pressure of abscess may impair blood supply
    - c. Treatment is drainage over point of maximal tenderness — lateral if possible

3. Subcutaneous abscess — incise and drain with care not to injure digital nerve. Be alert to possibility of foreign body
4. Tenosynovitis — infection of tendon sheath
  - a. Diagnostic signs (Kanavel's signs)
    - i. Fusiform swelling of finger
    - ii. Finger held in slight flexion
    - iii. Pain with passive extension
    - iv. Tenderness over flexor tendon sheath
  - b. Treatment is to open and irrigate tendon sheath. Untreated infection can destroy the tendon within hours
5. Human bite
  - a. Have high index of suspicion — patients are often unwilling to admit being in a fight. Most common site over a knuckle
  - b. Debride, cleanse thoroughly, culture
  - c. Must rule out penetration of joint space — may need to explore in OR
  - d. Broad spectrum antibiotics — often I.V.
  - e. Do not suture wound

#### V. FRACTURES

- A. General principles
  1. Inspect, palpate, x-ray in multiple planes — AP, true lateral, oblique
  2. Reduce accurately
  3. Immobilize for healing
  4. Hand therapy to maintain motion
- B. Specific fractures
  1. Metacarpal fractures
    - a. Boxer's fracture — fracture of 4th or 5th metacarpal neck. Can accept up to 30 degrees of angulation. Treatment can range from gentle protective motion if minimally displaced to closed reduction and cast to open reduction and internal fixation
    - b. Metacarpal shaft fractures — must check for rotatory deformity. Flex all fingers. If involved finger overlaps another, there is rotation at the fracture site which must be reduced. Unstable fractures must be fixed with pins or plates and screws

2. Phalangeal fractures
  - a. Unstable fractures require internal or percutaneous fixation
  - b. Joint surfaces should be anatomically reduced
3. Tuft fractures (distal phalanx)
  - a. If crushed, mold to shape
  - b. Repair associated nailbed injury if needed
  - c. Splint for comfort (DIP only) for 1-2 wks

## VI. JOINT INJURIES

- A. Dislocation
  1. If already reduced, test for instability in range of motion and with lateral stress
  2. Most can be treated with closed reduction; open reduction can be necessary if supporting structures entrap the bone (e.g. metacarpal head through extensor mechanism)
- B. Ligamentous injury — usually lateral force
  1. Gamekeeper's thumb — rupture of ulnar collateral ligament of MP joint
  2. Wrist injury — multiple ligaments can be involved. Diagnosis may require arthrogram, arthroscopy, or MRI. Clinical diagnosis by pattern of pain, x-rays, palpation for abnormal movement
- C. Treatment
  1. Try to maintain controlled protected motion
  2. Unstable joint — immobilize for 3 wks. (some, e.g. thumb ulnar collateral ligament, might need operative repair)

## VII. CONGENITAL DEFECTS

- A. Classification system (Table 6-1)
- B. Common defects
  1. Polydactyly — most common. Duplication of fingers, usually border digits. Duplication of 5th finger is common autosomal dominant trait in African-Americans. Thumb duplication often requires reconstructive surgery
  2. Syndactyly — 2nd most common — May be simple, involving skin only, or complex, involving bone
- C. Treatment — goal to decrease deformity and improve function

- I. Failure of formation of parts
  - A. Transverse
  - B. Longitudinal
- II. Failure of separation of parts
- III. Duplication of parts
- IV. Overgrowth of parts
- V. Undergrowth of parts
- VI. Congenital constriction bands
- VII. Generalized skeletal abnormalities

Adapted from Swanson, A.B.: *J Hand Surg* 1:8, 1976.

**Table 6-1**

1. Some problems are treated in infancy — e.g. splinting for club hand, thumb reconstruction
2. Some treated in early childhood — e.g. separation of syndactyly
3. Some require multi-staged procedures — e.g. club hand

## VIII. HAND TUMORS

- A. Benign
  1. Ganglion cysts — most common
    - a. Synovial cyst of joint or tendon sheath
    - b. Treatment is excision
  2. Giant cell tumor
  3. Glomus tumors — of thermoregulatory neuromyoarterial apparatus. Presents with pain and temperature sensitivity
  4. Bone tumors — enchondroma, osteoid, osteoma
- B. Malignant
  1. Skin cancers (e.g. basal cell, squamous cell, melanoma)
  2. Malignant bone tumors are uncommon in hand

## IX. MISCELLANEOUS

- A. Rheumatoid arthritis — synovial hypertrophy can lead to nerve compressions (carpal tunnel syndrome), joint destruction. Hand surgeons get involved with synovectomy, joint replacement, carpal tunnel release

- B. Dupuytren's contracture
  - 1. Fibrous contraction of palmar fascia causes flexion contractures of fingers
  - 2. Treatment is surgical excision of involved fascia
- C. Nerve compressions — compression of nerve by overlying muscle, ligament or fascia
  - 1. Example: carpal tunnel — compression by transverse carpal ligament
  - 2. Diagnosis by symptoms and EMG
  - 3. Treatment options include splinting, steroid injections, surgery

## **CHAPTER 6 — BIBLIOGRAPHY**

### **UPPER EXTREMITY**

1. Achauer, B.H. *Plastic Surgery: Indications, Operations, Outcomes*. St. Louis: Mosby, 2000.
2. Aston, S.J. et al. (eds.) *Grabb and Smith's Plastic Surgery*. 5th Ed. Baltimore: Lippincott, Williams and Wilkins, 1997.
3. Green, D.P. *Operative Hand Surgery*. New York: Churchill Livingstone, 1996.
4. McCarthy, J. *Plastic Surgery*. (8 vols). St. Louis: Mosby, 1990.

\*Fig. 6-4 reprinted with permission from Marks, M.W., Marks, C. *Fundamentals of Plastic Surgery*: Philadelphia: W.B. Saunders Co., 1997.